

Mandibular incisor extraction: indications and long-term evaluation

Jose-Antonio Canut

University of Valencia, Spain

SUMMARY The extraction of a lower incisor constitutes a therapeutic alternative limited to certain occlusal situations, i.e. supernumerary incisors, tooth size anomalies (peg-shaped upper laterals), ectopic eruption and anterior crossbites. The effect of the extraction of a single incisor on the out of retention alignment of lower anterior teeth was studied in 26 treated cases. Initial (T1), final (T2) and 5–8 years out of retention (T3) dental casts were measured. Mean crowding at the start of treatment (T1=3.86 mm) relapsed out of retention (T3=1.49 mm), with a net mean improvement of 2.37 mm. Little's irregularity index at the start of treatment (T1=6.44) relapsed out of retention (T3=2.53), with a net mean improvement of T1–T3=3.91. Alignment stability seems to be better than that achieved in cases subjected to premolar extraction.

Introduction

The extraction of healthy teeth has constituted a treatment alternative for over a century. Thus, in 1757 Bourdet, a disciple of Pierre Fauchard, recommended the removal of the premolars to relieve crowding. Likewise, Hunter (1835) extracted the first premolars to allow incisor retrusion in cases of posterior protrusion. Almost two centuries later, Hahn (1942) advocated the removal of a mandibular incisor to close the space and thus reduce the anterior dentition. This procedure afforded lingual movement and elevation of the anterior teeth, and so helped to correct Class III malocclusions.

The extraction of the lower incisors constitutes a therapeutic alternative in treating certain anomalies. It is not a standard approach to symmetrically treating most malocclusions, but in certain clinical situations the therapeutic aims must be adjusted to individual patient needs—even when this means that achieved final occlusion is not ideal. As pointed out by Kokich and Shapiro (1984), the deliberate extraction of a lower incisor in certain cases allows the orthodontist to improve occlusion and dental aesthetics with a minimum of orthodontic action. In all cases, however, a diagnostic set-up is required to predetermine the precise occlusal possibilities.

Indications

Experience has been obtained in the treatment of patients with three incisors due to agenesis of a lower incisor, accepting the occlusal and aesthetic compromise of the final interdigitation (Bahreman, 1977). The extraction of a mandibular incisor seems to be indicated in four types of clinical situation: anomalies in the number of anterior teeth; tooth size anomalies; ectopic eruption of incisors; and moderate Class III malocclusions.

Anomalies in the number of anterior teeth

The presence of a supernumerary lower incisor requires its extraction in order to achieve good occlusal alignment. A more common situation involves the absence of an upper lateral tooth, which may be replaced with a prosthesis; alternatively, the space can be closed orthodontically. The extraction of a lower incisor would be indicated in the latter case, in order to co-ordinate the occlusion of the incisors (Figure 1).

Tooth size anomalies

Discrepancies in the mesiodistal size of the six anterior teeth may be corrected by extracting a lower incisor. The disproportion, as reflected by Bolton's Index (1958), is established by the relative macrodontia of the lower incisors, or microdontia of the upper laterals. The fracture

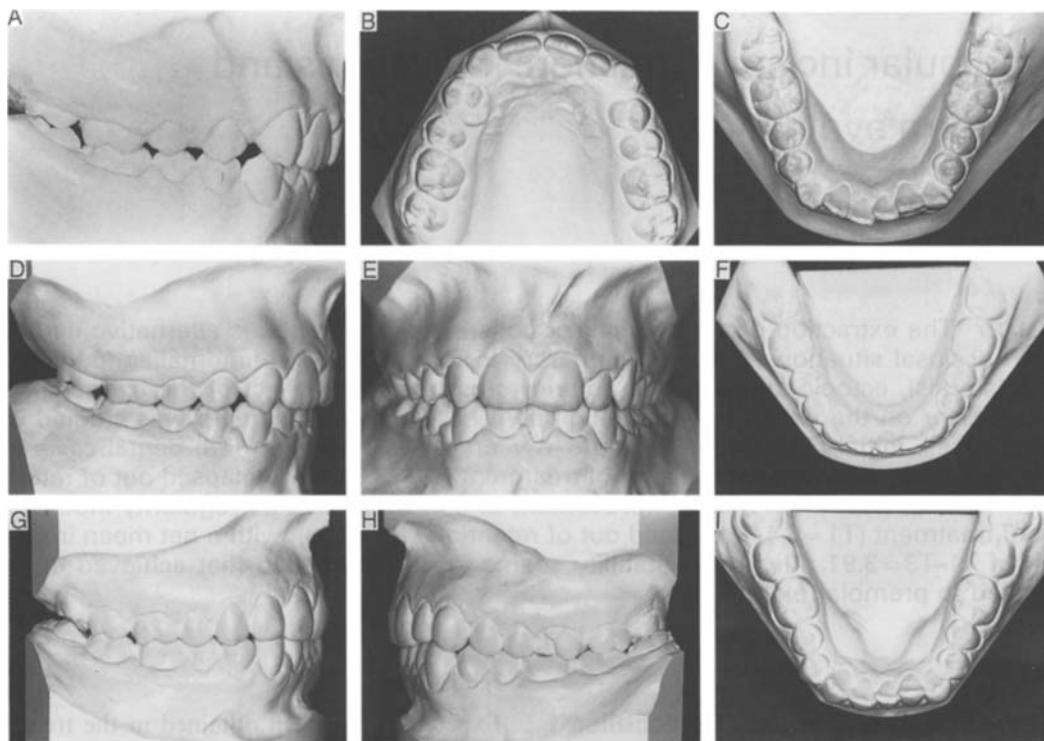


Figure 1 11-year-old girl with agenesis of upper right lateral and microdontia of left lateral; crowding in the lower arch (A, B, C). Occlusion after treatment with extraction of left lower incisor (D, E, F). Occlusion 16 years later with slight relapse of the lower alignment (G, H, J).

or morphological defect of a mandibular incisor indicates its extraction in cases of crowding.

Ectopic eruption of incisors

The transposition of anterior teeth, particularly of the canines, or the severe malpositioning of a lower incisor, indicates extraction to protect the long-term survival of the dentition.

Moderate Class III malocclusions

Anterior crossbite or an edge-to-edge relation of the incisors with a tendency towards anterior open bite is another indication for incisor extraction. The occlusion improves on shortening the length of the mandibular arch, which retrudes the position of the lower incisors (Figure 2).

Objectives

Bearing in mind the limitations of this infrequent therapeutic alternative in orthodontic practice, the long-term results obtained follow-

ing lower incisor extraction have been evaluated. The specific objective of the present study was to analyse anterior alignment several years out of retention, in order to establish the improvement and stability achieved in patients subjected to removal of a lower incisor.

Subjects and methods

The study sample consisted of 26 patients treated by Edgewise appliance therapy with extraction of one mandibular incisor. The patients were selected from the author's private practice after reviewing 3000 dental casts of consecutively treated cases during the past 20 years. Only cases with plaster models before treatment, at the time of appliance removal and a minimum of 5 years out of retention were recorded.

The patients were mostly young, with a mean age at the start of treatment of $T1 = 12.5$ years. Patient age at the end of treatment and at the last follow-up out of retention was $T2 = 15.1$

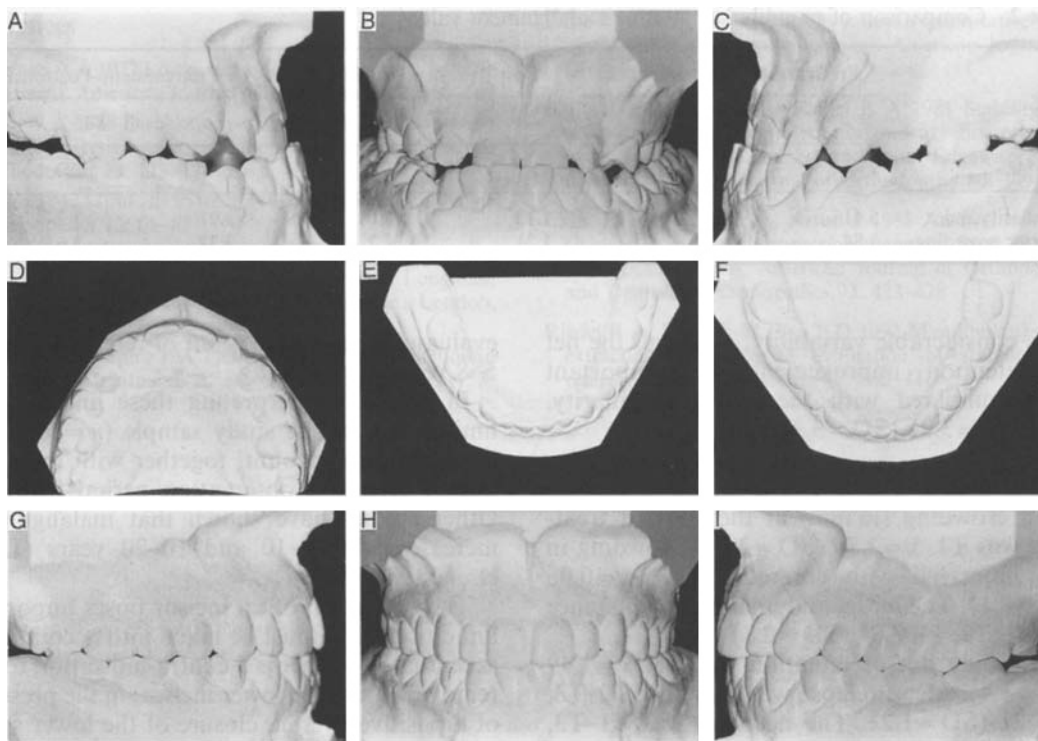


Figure 2 13-year-old girl with Class III malocclusion and anterior crossbite (A, B, C). Upper premolars were impacted (D), the right second deciduous molar was present (E) and the left central incisor was extracted. The occlusion at 37 years of age (F, G, H, I) with good alignment and occlusion.

and T3=25.4 years, respectively. Edgewise appliance technique was used in treating all cases.

Digital calipers (Mitutoyo, Japan) calibrated to 0.01 mm were used in measuring all parameters. The irregularity index described by Little (1975), which measures the displacement of anatomic contact points of lower anterior teeth, was applied to estimate dental cast alignment before and after treatment, and out of retention. The measurement of crowding was also applied by the conventional method to the lower arch.

Results

Irregularity index

The mean irregularity index at the start of treatment was T1, $\bar{x}=6.44$ ($SD=3.4$), i.e. most of the 26 patients treated (Table 1) exhibited great irregularity. At the end of correction the mean irregularity index had decreased markedly to T2, $\bar{x}=0.59$ ($SD=0.6$), with a difference of T1-T2, $\bar{x}=5.41$ ($SD=3.1$) (Table 2).

Irregularity out of retention increased at T3, $\bar{x}=2.53$ ($SD=3.1$), i.e. relapse corresponded to T2-T3, $\bar{x}=1.13$ ($SD=2$). The results presented

Table 1 Mandibular anterior malalignment values.

Variable	Pretreatment		Post-treatment		Postretention	
	T1		T2		T3	
	\bar{x}	SD	\bar{x}	SD	\bar{x}	SD
Irregularity index	6.44	3.4	0.59	0.6	2.53	3.1
Anterior crowding	3.86	2.1	0.06	0.1	1.49	1.4

Table 2 Comparison of mandibular anterior malalignment values.

Variable	Pretreatment–Post-treatment		Post-treatment–Postretention		Pretreatment–Postretention	
	T1		T2		T3	
	\bar{x}	SD	\bar{x}	SD	\bar{x}	SD
Irregularity index	5.41	3.1	1.13	2.0	3.91	3.3
Anterior crowding	3.84	2.3	1.21	1.2	2.37	2.6

show considerable variability, although the net post-retention improvement was important when compared with the initial irregularity, T1–T3, $\bar{x}=3.91$ (SD=3.3).

Crowding

Mean crowding (in mm) at the start of treatment was T1, $\bar{x}=3.86$ (SD=2.1). Crowding in turn improved with correction: T2, $\bar{x}=0.06$ (SD=0.1). The initial and final mean difference was T1–T2, $\bar{x}=3.84$ (SD=2.3).

Crowding out of retention was T3, $\bar{x}=1.49$ (SD=1.4). Mean relapse was therefore T2–T3, $\bar{x}=1.21$ (SD=1.2). The net gain was T1–T3, $\bar{x}=2.37$ (SD=2.6).

No clinically significant correlations were found when comparing the pretreatment crowding index and crowding with out of retention changes in all dental cast parameters, i.e. values of irregularity and crowding, Angle Class, gender or length of treatment.

Discussion and clinical implications

When comparing dental cast measurement of a single mandibular incisor extraction with the results reported by Riedel *et al.* (1992) in 24 cases, the changes observed are different. Thus, the irregularity index obtained by Riedel was T1=1.72, versus T1=6.44 in this series, i.e. initial incisor malalignment was more severe. The changes observed before and after treatment were T1–T2=1.44 and 5.41 in Riedel's series and this sample, respectively. In both series improvement was important. During the out of retention period there was a significant increase in irregularity: T2–T3=0.33 and 1.13 in Riedel's series and this sample, respectively. The remaining improvement is about 60 per cent of initial irregularity. In both groups the out of retention irregularity is clinically acceptable, with the difference that the Seattle study

evaluates cases 10 years out of retention, versus 5–8 years in this study.

In clinically interpreting these findings, the limited size of the study sample ($n=26$) must be taken into account, together with the short out of retention observation period involved. Other studies have shown that malalignment increases after 5–10 and 10–20 years (Little *et al.*, 1981, 1988).

The extraction of an incisor poses important limitations that must be taken into account. An accentuated overjet is a contra-indication to the removal of a single lower incisor; in the presence of a positive overjet, closure of the lower space will increase the overjet. On removing an incisor, the canine displaces mesially, and canine functional protection is lost. A diagnostic set-up of the final occlusal status must be evaluated. In certain cases, and particularly among adults, the space either fails to close or else opens up with ease; a visible diastema thus results in an area of considerable aesthetic and periodontal importance.

In the event of performing extractions, a number of clinical considerations lend support to the convenience of removing an incisor in place of a premolar. One way of preventing relapse is to extract an incisor with extreme malpositioning, which moreover limits the sometimes unnecessary movement of many teeth; correction thus becomes more circumscribed to a specific dentition zone. The loss of gingival tissue or the disappearance of the external alveolar lamina constitutes an additional indication for extraction of the affected incisor.

Address for correspondence

Prof. Jose A. Canut
Grabador Esteve, 10
46004 Valencia, Spain

References

- Bahreman A A 1977 Lower incisor extraction in orthodontic treatment. *American Journal of Orthodontics* 72: 560–567
- Bolton W A 1958 Disharmony in tooth size and its relation to the analysis and treatment of malocclusion. *Angle Orthodontist* 28: 113–130
- Hahn G 1942 Problems in treatment of malocclusion. *Angle Orthodontist* 12: 61–82
- Hunter J 1835 Of the irregularity of the teeth. In: Palmer J F (ed) *Natural history of human teeth*. Longman, Reece, Orme, Brown, Green and Longman, London, pp. 88–92
- Kokich V G, Shapiro P A 1984 Lower incisor extraction in orthodontic treatment. *Angle Orthodontist* 54: 139–153
- Little R M 1975 The irregularity index: a quantitative score of mandibular anterior alignment. *American Journal of Orthodontics* 68: 554–563
- Little R M, Wallen T R, Riedel R A 1981 Stability and relapse of mandibular anterior alignment – first premolar extraction cases treated by traditional Edgewise orthodontics. *American Journal of Orthodontics* 80: 349–365
- Little R M, Riedel R A, Årtun J 1988 An evaluation of changes in mandibular anterior alignment from 10 to 20 years postretention. *American Journal of Orthodontics and Dentofacial Orthopedics* 93: 423–428
- Riedel R A, Little R M, Bui T D 1992 Mandibular incisor extraction—postretention evaluation of stability and relapse. *Angle Orthodontist* 62: 103–116